

Bullous Pemphigoid: A Review of its Diagnosis, Associations and Treatment

Philippe Bernard¹ · Frank Antonicelli²

© Springer International Publishing Switzerland 2017

Abstract Bullous pemphigoid (BP) is the most common autoimmune subepidermal blistering disease in Western countries, and typically affects the elderly. BP is immunologically characterized by tissue-bound and circulating autoantibodies directed against either the BP antigen 180 (BP180, or BPAG2) or the BP antigen 230 (BP230, or BPAG1e), or even both, which are components of hemidesmosomes involved in the dermal–epidermal cohesion. Risk factors for BP include old age, neurologic diseases (dementia, Parkinson’s disease, cerebrovascular disease), and some particular drugs, including loop diuretics, spironolactone and neuroleptics. The spectrum of clinical presentations is extremely broad. Clinically, BP is an intensely pruritic erythematous eruption with widespread blister formation. In the early stages, or in atypical, non-bullous variants of the disease, only excoriated, eczematous or urticarial lesions (either localized or generalized) are present. The diagnosis of BP relies on immunopathologic findings, especially based on both direct and indirect immunofluorescence microscopy observations, as well as on anti-BP180/BP230 enzyme-linked immunosorbent assays (ELISAs). BP is usually a chronic disease, with spontaneous exacerbations and remissions, which may be accompanied by significant morbidity. In the past decade, potent topical corticosteroids have emerged as

an effective and safe first-line treatment for BP, but their long-term feasibility is still controversial. Newer therapeutic agents targeting molecules involved in the inflammatory cascade associated with BP represent future alternatives to classical immunosuppressant drugs for maintenance therapy.

Key Points

Bullous pemphigoid (BP), the main autoimmune bullous disease, preferentially involves elderly patients and is significantly associated with neurological disorders, which also represent a major prognostic factor.

Diagnosis of BP relies on immunopathologic examinations, particularly direct and indirect immunofluorescence microscopy, as well as anti-BP180/BP230 enzyme-linked immunosorbent assay (ELISAs).

The therapeutic options for BP include not only topical or systemic corticosteroids but also immunosuppressive or immunomodulatory drugs in severe or relapsing cases.

✉ Philippe Bernard
pbernard@chu-reims.fr

¹ Department of Dermatology and Reference Centre for Autoimmune Bullous Diseases, Robert Debré Hospital, University of Reims Champagne-Ardenne, Cedex, France

² Laboratory of Dermatology, EA7319 Derm-I-C, University of Reims Champagne-Ardenne, 51 rue Cognacq Jay, 51095 Cedex, France

1 Introduction

Bullous pemphigoid (BP) is the most common autoimmune subepidermal blistering disease of the skin that has emerged as a paradigm of organ-specific autoimmune

disease [1, 2]. It is associated with a humoral and cellular immune response directed against two well-characterized self-antigens: BP antigen 180 (BP180, also called BPAG2 or type XVII collagen) and BP antigen 230 (BP230, also called epithelial isoform of BPAG1, BPAG1e) [3–7]. These two antigens are components of the hemidesmosomes, which are adhesion complexes promoting epithelial–stromal adhesion in stratified and other complex epithelia. Almost all patients with BP have circulating immunoglobulin (Ig) G autoantibodies that bind to BP180, especially to the immunodominant non-collagenous NC16A extracellular domain of this protein [8–16]. Both in vitro and in vivo studies provided strong evidence for the pathogenic role of BP180 autoantibodies [17–21]. Although the annual incidence of BP was estimated to be between 6 and 20 new cases per million people, recent studies performed in some European countries suggest a two- to fivefold increase in these figures (Germany, France, UK) [22–30]. In this review, we shall attempt to critically describe and discuss the clinical presentation, associations, diagnosis, and treatment of BP. A comprehensive search of the literature was performed using the MEDLINE, EMBASE and Cochrane Library databases. The following search criterion was used: [“Pemphigoid, Bullous” (MeSH)]. The search was limited to English-language studies published from inception to 1 August 2016. Additional studies were identified from manual searches of references in the retrieved articles.

2 Clinical Features

BP is typically a disease of the elderly, with an onset after 75 years of age in most European series, and with an apparent higher predominance in women than in men [26–28]. The disease also occurs in young adults or children, but rarely [31–33]. BP usually presents with a generalized pruritic bullous skin eruption, and is potentially associated with (significant/important) morbidity. The clinical presentation may be quite polymorphic, particularly during the early stages of the disease or in atypical variants, in which typical blistering lesions may be absent (Table 1) [31, 34]. During the prodromal, non-bullous phase of BP, signs and symptoms are frequently non-specific, with mild to severe pruritus either alone or in association with eczematous, papular and/or urticarial cutaneous lesions that may persist for several weeks or months. In approximately 20% of patients, these non-specific skin lesions may remain as the only signs of the disease without obvious skin blistering at the time of BP diagnosis [27, 28]. The bullous stage of BP is characterized by the development of vesicles and bullae, which mainly occur on erythematous skin together with urticarial papules

and plaques that occasionally assume an annular pattern. The blisters are tense, up to 1–4 cm in diameter, contain a clear fluid, and ending in eroded and crusted areas. The lesions are frequently bilateral, and they predominate on the flexural aspects of the limbs and the lower trunk, including the abdomen. Involvement of the oral cavity is observed in 10–30% of patients [2, 7, 31, 34]. Conjunctival, nasal, pharyngeal, esophageal and anogenital mucosae are very rarely affected. BP may occasionally be localized around stomas or irradiated areas, limited to the pretibial area, to the umbilical area, or to the palmoplantar region mimicking dyshidrosiform eczema, or to the vulvar region in young girls [31, 34–39]. Several generalized atypical, non-bullous variants of BP have also been described, including multiple, grouped, tense vesicles with a symmetric distribution that resembles dermatitis herpetiformis (‘vesicular pemphigoid’), intertriginous vegetating plaques (‘pemphigoid vegetans’), papular or nodular lesions without blisters, non-bullous erythroderma (‘erythrodermic BP’) or toxic epidermal necrolysis-like BP [34, 37, 40–44].

3 Risk Factors and Associated Conditions

3.1 Age

Old age is a major, and even the most important, risk factor for the occurrence of BP [24, 26, 28]. This was first demonstrated in a retrospective study based on both the age- and gender-specific incidences of BP conducted in two regions in Germany, which showed that the risk for BP occurrence increased for patients above the age of 60 years, and that the relative risk for patients over 90 years of age appears to be approximately 300-fold higher than for those patients 60 years of age or younger [24]. Further studies, also conducted in European countries, confirmed that the risk of BP occurrence increases rapidly beyond the age of 80 years [26, 28], with an incidence rate over 300 cases per million person-years among people aged 80 years or older. In fact, BP should not be considered as a rare disease in the elderly population [28].

3.2 Neurologic Diseases

In the past 10 years, several hospital- or population-based studies have underlined the association between BP and neurologic or psychiatric disorders [45–57]. Overall, 22–46% of BP patients had at least one neurologic disease, including dementia (especially Alzheimer’s disease), Parkinson’s disease, and cerebrovascular disease [45, 48, 50–52, 54]. In all these series, BP followed the onset of the neurological disease at intervals varying from a few months to more than 5 years [49]. Patients with an

Table 1 Unusual clinical variants of bullous pemphigoid

Generalized lesions
<i>Dyshidrosiform pemphigoid</i> : palmoplantar vesicles and bullae
<i>Pemphigoid vegetans</i> : intertriginous vegetating plaques
<i>Pemphigoid nodularis</i> : prurigo nodularis-like lesions
<i>Vesicular pemphigoid</i> : dermatitis herpetiformis-like presentation
Large erosive toxic epidermal necrosis-like lesions
<i>Papular pemphigoid</i>
<i>Eczematous pemphigoid</i>
<i>Erythrodermic pemphigoid</i>
<i>Lichen planus pemphigoides</i>
Localized lesions
Pretibial
Vulvar
Peristomal
Umbilical
Distal end of amputated limb ^a
Paralyzed limb
Sites of radiotherapy ^b
Brunsting–Perry form ^c

^a Also referred to as ‘stump’ pemphigoid

^b Radiotherapy can also provoke a generalized form of pemphigoid

^c Also clinical variant of mucous membrane (cicatricial) pemphigoid

associated dementia were older and had a lower Karnofsky index [45, 56], and a coexistent neurological disease and/or dementia were associated with a higher mortality, although such association modified neither the type of the disease nor the total duration of the treatment [56]. In case-control studies and a recent meta-analysis [57], BP was significantly associated with neurological disorders as a whole [48, 53, 55, 57], Parkinson’s disease [50–54, 57], dementia [50–54, 57], stroke [50, 51, 54, 57], epilepsy [57], or psychiatric disorders (unipolar and bipolar disorders) [52], with odds ratios (ORs) ranging from 1.8 to 10.7 according to the associated neurologic disorder (Table 2). A strong association with multiple sclerosis was also observed in the only population-based study, which was conducted in the UK [51], and in a meta-analysis [57]. In addition, several case-reports and small case-series have suggested an association between BP and amyotrophic lateral sclerosis or Shy–Drager syndrome, which was not confirmed in case-control studies, likely because of a lack of statistical power due to the rarity of these diseases. Thus, BP seems to be associated with degenerative neurological diseases that may involve autoimmune mechanisms, such as Parkinson’s disease and Alzheimer’s disease. Specific neuronal antibodies have been found to accumulate within neurons in Alzheimer’s disease and may initiate neuronal degeneration. Neuronal variants of BP230 are expressed in the central and peripheral nervous systems [58, 59]. Therefore,

an autoimmune response initially directed against the neuronal isoform of BPAG1 (BPAG1-n) encoded by the dystonin gene may secondarily trigger an autoimmune response against the epithelial isoform of BPAG1. The rupture of tolerance induced by neuronal degeneration or destruction of the brain parenchyma in some neurological disorders may explain the delayed development of BP after the onset of the neurological symptoms. Together, these clinical and biological findings strongly suggest that neurologic diseases may represent a true risk factor for BP, possibly through the development of a humoral autoimmune response in the nervous system, which could subsequently spread to involved skin.

3.3 Drugs

In some patients, systemic medications are suspected to lead to the development of BP [52, 60–64]. From single case reports, at least 50 drugs have been suspected to be associated with the development of BP, including diuretics (e.g. furosemide, spironolactone), analgesics, D-penicillamine, antibiotics (e.g. amoxicillin, ciprofloxacin), potassium iodide, captopril, tumor necrosis factor (TNF) inhibitors and, more recently, the antidiabetic dipeptidyl peptidase-4 inhibitors (gliptins) [60, 61]. Recurrence of BP lesions following drug rechallenge has been occasionally observed with some medications (e.g. spironolactone).

Table 2 Factors significantly associated with bullous pemphigoid in case-control studies

Factor	Odds ratio	References
Old age	ND	[24, 26]
Neurologic diseases	6.9–10.5	[48, 53, 55, 57]
Dementia (including Alzheimer's disease)	2.2–6.8	[50–54, 57]
Parkinson's disease	2.2–9.0	[50–54, 57]
Cerebrovascular disease	1.8–3.3	[50, 51, 54, 57]
Psychiatric disorders (unipolar, bipolar)	5.2	[52, 57]
Epilepsy	1.7–7.8	[49–51, 57]
Chronic drug intake		
Psycholeptics (phenothiazines)	3.7	[52]
Spironolactone	2.3–3.1	[52, 61]
Loop diuretics (furosemide, bumetanide)	2.0–3.8	[62]
Malignant diseases (total)	ND	[65]
Hematological malignancies	2.5	[69]
Psoriasis	2.0	[50]
Diabetes mellitus	3.5	[75]

ND not determined

Two French, prospective, multicenter, case-control studies assessing the drugs used on a long-term basis prior to the onset of the disease, found, in multivariate analysis, that the chronic use of either the aldosterone antagonist spironolactone (ORs from 2.3 to 3.1) or phenothiazine psycholeptics with aliphatic side chains (OR 3.7) were significantly associated with the occurrence of BP (Table 2) [52, 62]. In contrast, in a UK retrospective case-control study, only loop diuretics (furosemide, bumetanide), but not aldosterone antagonists, were found to be associated with the development of BP, independently of age, sex, and neurologic or cardiovascular disease (OR 3.8) [63]. The apparent discrepancy between these results may be partly explained by differences in the diuretic class more frequently prescribed in each country. In recent years, the emerging drugs that have been increasingly reported in association with the development of BP are dipeptidyl peptidase-4 inhibitors (vildagliptin, sildagliptin, saxagliptin), which are used to treat type 2 diabetes mellitus [61, 64]. Most of the cases were reported with vildagliptin, although sildagliptin is the most prescribed gliptin, at least in Europe. Very recently, a case-non-case study from the French pharmacovigilance database with disproportionality analyses confirmed a strong signal for an increased risk of developing BP during dipeptidyl peptidase-4 inhibitor exposure [64]. Again, the signal was higher with vildagliptin (reporting OR 225.3) than with the other gliptins. Interestingly, for the first time in France, this study also showed an association between furosemide exposure and BP onset (reporting OR 3.3) [64]. However, a major limitation of this study is the considerable underreporting of cases of cutaneous drug reactions to the French

pharmacovigilance database, which is a source of bias. Consequently, large, prospective, case-control studies are still mandatory to definitively confirm that dipeptidyl peptidase-4 inhibitors are associated with the development of BP. Although it is likely that some identified drugs act as triggers for BP development, more studies are needed to determine the processes through which these drugs can cause this specific autoimmune skin disease, e.g. by modifying the immune response or altering the antigenic properties of the epidermal basement membrane.

3.4 Internal Malignancies

The association of internal malignancies with BP is probably primarily related to the older age of the patient since both BP and cancer are diseases of the elderly. Indeed, for years, numerous case reports have described BP in association with a variety of malignancies, whereas in a few of these reports, there was a parallel clinical course between internal malignancy and BP outcome [65]. In contrast, case-control studies revealed some conflicting results about the possible association of BP with internal malignancies. A hospital-based case-control study in the UK found a significant increase of malignancies (both hematological and non-hematological) in patients with BP compared with controls (17% vs. 5.4; OR 3.6), but the rate of malignancy was surprisingly low in controls and the sample size was limited [66]. In contrast, a large Swedish case-control study revealed that BP was not associated with malignancy (relative risk of cancer 0.84) [67]. In Japanese patients, there was a low association between BP and gastric cancer, the most common cancer in Japan, but

ORs were not calculated [68]. Furthermore, in a recent, nationwide English record linkage study, there was no increased risk of concurrent and subsequent malignant cancers in BP patients compared with the reference cohort (relative risk of cancer 1.0) [69]. Finally, a large population-based, case–control study conducted in Germany from the database of a major health insurance company showed no association between BP and non-hematological malignancies, whereas there was an association of BP with hematological malignancies, notably Hodgkin disease, non-follicular lymphoma, mature T/NK-cell lymphoma, and myeloid leukemia (OR 2.5) [70]; however, considering that in half of the BP patients the hematological malignancy preceded the diagnosis of BP, it is unlikely that BP or its treatment had triggered this malignancy. In clinical practice, patients with BP should be carefully up-to-date, both clinically and using age-related cancer screening tests recommended for the general population.

3.5 Other Associated Conditions

BP has been found in association with certain dermatoses, such as psoriasis and lichen planus, and the bullae may be localized to the psoriatic plaques or lichenoid papules, representing a Koebner phenomenon. The coexistence of lichen planus and BP is referred to as lichen planus pemphigoides. A significant association between BP and psoriasis was shown in two case–control studies, including a recent nationwide, population-based study conducted in Taiwan (OR 2.02; 95% confidence interval 1.5–2.6) [50]. To explain this association, it was speculated that a chronic inflammatory process at the dermal–epidermal junction results in the exposure of antigens to autoreactive T lymphocytes, leading to a secondary immune response (‘epitope spreading’ phenomenon) [54, 71, 72]. Alternative hypotheses have been proposed to try to explain the concurrence of psoriasis vulgaris and BP, including the triggering role of antipsoriatic treatments such as tar or psoralen plus ultraviolet A (PUVA) therapy [65]. More recently, the possible role of T helper (Th) 17 cells in patients with psoriasis and interleukin (IL)-17 cytokine in BP may represent a pathophysiological link between the two diseases, with potential therapeutic perspectives for BP [73]. In contrast to psoriasis, lichen planus has never been demonstrated to be significantly associated with BP [50], probably because of a lack of statistical power due to its rarity; however, a pathogenic link remains possible through autoantibodies against BP180 antigen [74].

Occasionally, BP has been reported in patients with other autoimmune disorders such as rheumatoid arthritis, Hashimoto’s thyroiditis, dermatomyositis, Grave’s disease, autoimmune thrombocytopenia or neutropenia, vitiligo, and lupus erythematosus. It is thought that these

associations are not fortuitous, but reflect a genetically determined susceptibility to develop autoimmune diseases. Nevertheless, a case–control study did not find any increased risk for autoimmune disorders in those with BP [75]. An association of BP with diabetes mellitus has been suspected because glycation of proteins of the dermal–epidermal junction could possibly increase their immunogenicity. In a single case–control study, the occurrence rate of primary diabetes mellitus was higher in patients with BP than in controls (20 vs. 2.5%; OR 3.5), but the sample size was small and the control subjects were not matched [76]. This association was not confirmed in further case–control studies [48, 50, 52, 77] and it is likely that the high rate of diabetes mellitus in BP patients is related to the advanced age of patients with BP. Finally, in some patients, BP appears to be triggered by trauma, burns, radiotherapy, or ultraviolet (UV) irradiation (including PUVA) [65].

4 Diagnosis

A proper diagnosis of BP is based on a combination of clinical features, a positive direct immunofluorescence (IF) microscopy of a perilesional skin, and the detection of specific circulating IgG anti-basement membrane autoantibodies by either indirect IF microscopy studies or by enzyme-linked immunosorbent assay (ELISA). In the majority of cases, the latter tests are sufficient for a correct diagnosis. Nevertheless, in a minority of patients (approximately 10%) in whom both indirect IF microscopy and ELISAs are negative, additional immunopathological analyses (e.g. n-serration pattern analysis, fluorescence overlay antigen mapping [FOAM] technique) are helpful and are required to demonstrate an autoantibody response to BP180 and/or BP230. The initial evaluation of patients should encompass a complete physical examination, a search for risk factors and comorbidities, and, whenever possible, the assessment of the initial damage and extent of BP, e.g. by using the BP Disease Activity Index BPDAI [78, 79] or daily blister count [80, 81].

4.1 Clinical Criteria

BP typically presents with tense, mostly clear skin blisters, in conjunction with erythematous or urticarial plaques that are associated with moderate to severe pruritus [2, 31, 34]. The presence of distinct clinical features in patients with an acquired subepidermal blistering disease associated with positive direct IF microscopy provides very useful diagnostic clues for the diagnosis of BP. In patients with a subepidermal blistering disease associated with linear deposits of IgG or C3 along the epidermal basement membrane, a French study found that a diagnosis of BP

could be made with a sensitivity of 90% and a specificity of 83% if three of the following clinical criteria are present among the absence of skin atrophy: the absence of mucosal involvement, the absence of head and neck involvement, and age >70 years [82]. With an estimated incidence of BP among subepidermal autoimmune bullous diseases of 80% [22, 23], the presence of three of the four significant criteria allows the diagnosis of BP, with a positive predictive value of 95% [82]. Afterwards, these clinical criteria were validated according to immunoblot analysis of the sera of BP patients [83], and were used for inclusion of patients in large clinical studies, including randomized clinical trials [16, 27, 28, 52, 80, 81, 84–86]; however, these clinical criteria require the presence of recent blisters, which are not present in approximately 20% of BP patients at the time of diagnosis [27, 28, 87]. In contrast, their diagnostic value appears inoperative or questionable in patients with eczematous, urticarial, excoriated or erosive skin lesions without obvious blistering and linear deposits of immunoreactants along the epidermal basement membrane by direct IF [88]. In these non-bullous presentations, the diagnosis of BP critically relies on positive direct IF microscopy studies and the demonstration of serum autoantibodies against BP180 and/or BP230 antigens [11, 89].

4.2 Light and Direct Immunofluorescence (IF) Microscopy

In the non-bullous phase, or in atypical variants of BP, light microscopy studies provide little specific information since only subepidermal clefts, eosinophilic spongiosis, and/or dermal infiltrates of eosinophils may occasionally be found. In biopsy specimens of an early bullae, a subepidermal blistering associated with an inflammatory infiltrate mostly composed of eosinophils, neutrophils and mononuclear cells is typically observed in the upper dermis, while the cavity of the bullae contains a net of fibrin with a variable cellular infiltrate [11, 31, 89].

In all patients, direct IF microscopy studies of perilesional, non-bullous skin disclose the presence of fine, linear, continuous deposits of IgG and/or C3 (and, more rarely, other Ig classes) along the epidermal basement membrane, with IgG4 and IgG1 as the predominant IgG subclasses represented. Direct IF microscopy studies of perilesional skin after treatment with 0.09% NaCl solution (referred to as salt-split skin) might be helpful in distinguishing BP from other autoimmune blistering disorders. In BP, immune deposits are found in the epidermal side (roof) or in both the epidermal and dermal (floor) sides of the split [90]. Close analysis of the linear fluorescence pattern along the epidermal basement membrane zone (BMZ) may allow the distinction of BP ('n-serrated'

staining pattern) from epidermolysis bullosa acquisita ('serrated' staining pattern) [91]. In atypical cases, a computer-aided FOAM technique may be helpful for confirming the diagnosis of BP in determining the localization of deposited immunoreactants more precisely [92].

4.3 Indirect IF Microscopy

For indirect IF studies, salt-split normal human skin is now the substrate of choice, rather than intact normal human skin and monkey esophagus, which are not useful for differentiating BP from other subepidermal bullous diseases. Circulating antibasement membrane autoantibodies of the IgG class, and, less frequently, of the IgA and IgE classes, are detectable in 60–80% of patients [5, 7, 15, 16, 59, 93–95]. These autoantibodies typically bind to the epidermal side or, less frequently, to both the epidermal and dermal sides of saline-separated normal human skin [7, 93, 94]. A multiplex IF BIOCHIP mosaic was recently commercially available, which is based on indirect IF with purified BP180 recombinant protein spotted on slide and transfected cells expressing BP230 [96].

4.4 Immunochemical Methods and Enzyme-Linked Immunosorbent Assays (ELISAs)

Using immunoblot and immunoprecipitation techniques from epidermis or keratinocyte extracts, 60–100% of the sera from patients with BP were shown to contain IgG autoantibodies that bound to BP180 and/or BP230 [3, 4, 7, 15, 97–100]. In addition, these sera may also contain specific IgA and IgE autoantibodies [34]. Recombinant forms of BP180 and BP230 expressed in prokaryotic or eukaryotic systems have been increasingly used for the detection of autoantibodies [5, 7, 15, 34], but nowadays, ELISAs have replaced immunoblot and immunoprecipitation techniques, which are technically much more demanding. These conventional, but not fully standardized immunochemical techniques, are only performed in specific cases of BP, such as for ELISA BP180-negative or BP230-negative serum samples or in investigative studies. ELISAs utilizing recombinant proteins that encompass specific regions of the BP antigens (e.g. the NC16A domain of BP180 and the C-terminus of BP180 or BP230) are now widely commercially available and enable rapid characterization of autoantibodies within the serum of patients with BP [5, 7–16, 34]. In contrast to immunoblotting, ELISA antigens are tested under native conditions, and, as a result, binding activity against conformational antigens is not lost. Using commercially available ELISAs, anti-BP180 autoantibodies are detected in 72–93% of BP cases [10, 12, 14, 16, 95, 101, 102], and serum levels at diagnosis have been correlated with disease

activity [16, 102, 103]. Overall sensitivity of the BP180-NC16A ELISA is comparable with that of indirect IF (with salt-split skin as a substrate) when the test is performed in unselected BP patients [59, 95]. Anti-BP230 autoantibodies are detected by ELISA in 57–63% of BP cases [16, 95, 102, 104–106]. BP230 ELISA scores at diagnosis did not correlate with disease activity [16] but seem to be associated with localized types of BP [9, 102]. Recent findings support that the contribution of the BP230-specific autoantibodies to the anti-BMZ antibody titer determined by means of indirect IF is greater than BP180-specific antibodies [16]. In routine practice, the combined use of an ELISA for BP230 protein increases the overall sensitivity of only 5–10%, and may only be recommended in case of negative BP180-ELISA [13, 16, 59, 102]. These ELISAs have been found to be fairly specific ($\geq 90\%$) in studies where control population included age- and sex-matched normal subjects or patients with various dermatoses in whom a BP had been excluded; however, low-titer, false-positive results are occasionally observed in healthy subjects and elderly patients with pruritic cutaneous eruptions [48, 107–109]. In addition, serum autoantibodies against the NC16A domain of BP180 are detected by ELISA in almost 40% of patients with mucous membrane pemphigoid [110].

4.5 Practical Approach to the Diagnosis of Bullous Pemphigoid

The clinical findings in the non-bullous phase of BP are usually non-specific and may mimic a variety of dermatoses, including drug reactions, contact dermatitis, prurigo, urticaria, arthropod reactions, or scabies. These disorders, as with acquired non-autoimmune blistering disorders (e.g. bullous arthropod bites, Stevens–Johnson syndrome, bullous drug eruptions, dyshidrotic eczema, porphyria cutanea tarda) are usually distinguished on the basis of the clinical history and setting, pathologic features, and, above all, the negative direct IF microscopy findings. The pemphigus group, paraneoplastic pemphigus, and dermatitis herpetiformis are easily differentiated on the basis of distinctive direct IF findings and clinical context. In elderly patients with the typical generalized blistering eruption, the diagnosis is easily made on the basis of clinical criteria (see above) and direct IF findings (Fig. 1). In localized and atypical variants of BP (see above), usually less than three of the four diagnostic criteria [82, 83] are present. In these atypical presentations, diagnosis of BP must be confirmed by the proper characterization of circulating autoantibodies or thorough analysis of tissue-bound antibodies by direct IF microscopy, e.g. n-serrated pattern or FOAM technique (Fig. 1).

The differentiation of BP from other autoimmune subepidermal blistering disorders, which share the same pattern of linear IgG and/or C3 deposits along the epidermal BMZ by direct IF microscopy, can sometimes prove challenging. In patients with both oral and cutaneous lesions, the differentiation of mucous membrane pemphigoid [111] from BP is sometimes difficult, and classification relies on the presence of an obvious scarring tendency of involved mucosal sites and limited skin involvement, as well as, occasionally, on the characterization of circulating autoantibodies [110, 112–116]. Besides, the inflammatory form of epidermolysis bullosa acquisita may closely resemble BP [117, 118]. It must be excluded on the basis of indirect IF microscopy on salt-split normal human skin (labeling of the dermal side of the split skin) [93, 94, 112], detection of serum autoantibodies against type VII collagen using specific ELISA or immunoblot analysis of dermal extracts [117–119], and/or close analysis of in vivo immune deposits by direct immunoelectron or IF microscopy [91, 92, 120]. A group of patients have been described with a skin eruption identical to that observed in BP, i.e. vesicles and tense blisters, as well as eczematous and urticarial papules and plaques, although they tend to be younger, and concurrent psoriasis may be frequent in patients from Japanese origin [121]. Conversely to patients with BP, these patients have circulating autoantibodies that specifically bind the dermal side of salt-split human skin. The targeted 200 kDa BMZ protein is the gamma 1 chain of laminin [122, 123].

Finally, another difficult issue is how to categorize the group of elderly patients with generalized pruritus (with or without skin lesions), in which circulating autoantibodies to the epidermal BMZ and reactivity with BP180 and/or BP230 are found, but routine IF microscopy remains negative [48, 108, 109, 124, 125]. In fact, the demonstration of circulating autoantibodies against these two BP autoantigens should not be regarded as a diagnostic criterion for BP in the absence of typical direct IF microscopy findings [87]. Some of these patients, with initially negative direct IF microscopy findings, eventually develop BP and could be thought of as having pemphigoid *incipiens*.

5 Treatment

BP is a chronic disease characterized by spontaneous exacerbations. It is a self-limiting disease that may last from several months to years [31, 126]. Approximately 30% of BP patients show a relapse during the first year of treatment [80, 81, 86, 126], with extensive disease and associated dementia as independent risk factors for relapse [86]. Furthermore, after cessation of therapy, approximately half of the patients show a relapse, which most

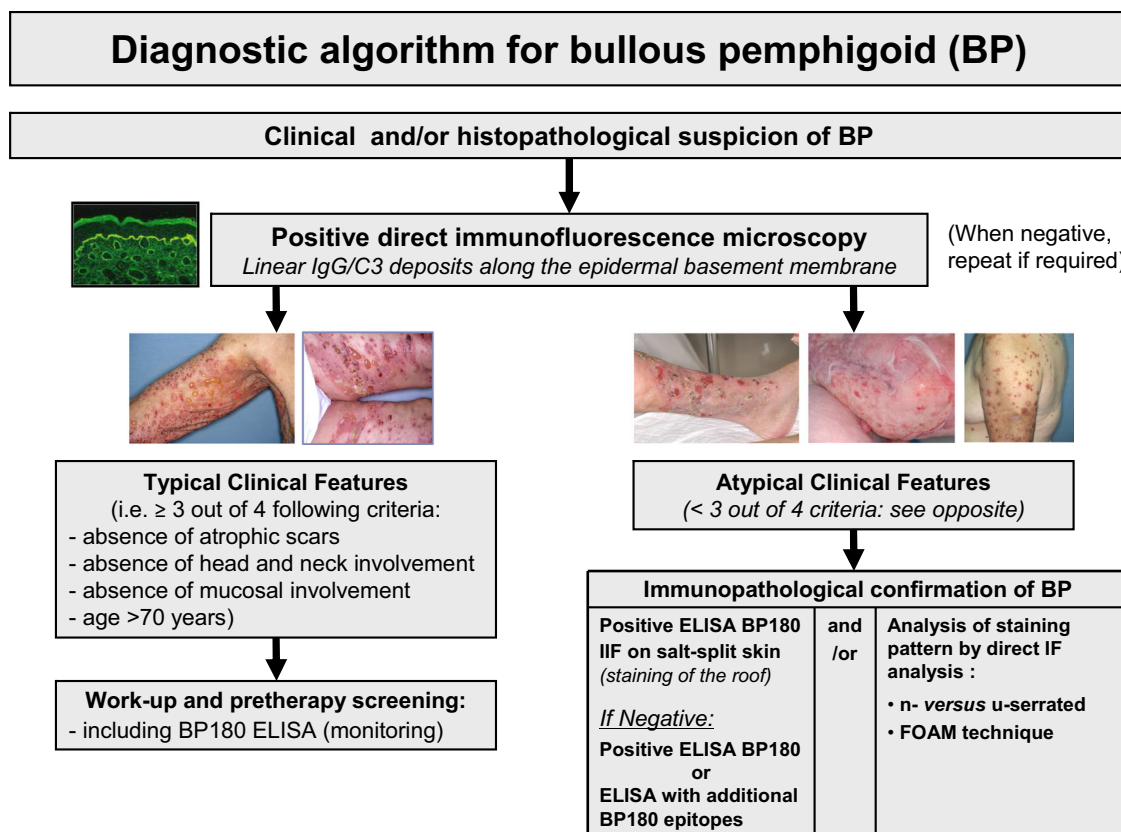


Fig. 1 Diagnostic algorithm for bullous pemphigoid. *ELISA* enzyme-linked immunosorbent assay, *FOAM* fluorescence overlay antigen mapping, *IF* immunofluorescence, *IIF* indirect immunofluorescence, *IgG* immunoglobulin G

frequently occurs within the first 3 months [85]. The mortality is considerable among elderly patients, especially in Western countries, and the estimated death rate during the first year varies between 10 and 40%, depending on the series [25, 26, 28, 29, 56, 80, 81, 84, 127–129]. Both aging and a Karnofsky score under 40 (range 0–100) significantly affect BP prognosis [84, 130, 131]. It is likely that comorbidities and practice patterns (use of systemic corticosteroids and/or immunosuppressive drugs) also influence overall morbidity and mortality [131]. In routine practice, the choice of treatment depends on the severity of the disease and the general health conditions and comorbidities. In addition, because of severe pruritus and the presence of blisters and eroded or impetiginized lesions, BP is often accompanied by significant morbidity, with a significant impact on quality of life, making proper management indicated and mandatory. The ideal treatment of BP should be effective and well tolerated in those elderly, fragile patients. Clinically, the major aim is to control both itch and skin lesions and to minimize the potential adverse events by avoiding aggressive, non-validated treatments. A Cochrane review updated in 2010 [132] highlighted the lack of evidence informing current treatment for BP since, to date, only 10 controlled, prospective, randomized

clinical trials have been published on the treatment of the disease [80, 81, 133–140]. Therefore, dealing with treatments for BP is actually based more on clinical experience or national or international guidelines [141–144] than on controlled studies. While the optimal duration of therapy has not been established, patients with BP usually need to be treated for approximately 6–12 months according to the presence of either mild or generalized disease, except in corticosteroid-refractory or corticosteroid-dependent cases [141–144]. This includes a maintenance phase in which a low-dose of either oral prednisone (<10 mg/day) or topical clobetasol propionate (10 g/week) is continued for 1–6 months after any evidence/cessation of clinically active disease. The therapeutic options for BP are divided into anti-inflammatory drugs, immunosuppressive or immunomodulatory drugs, and procedures to remove circulating pathogenic antibodies or inflammatory mediators (Table 3).

5.1 Corticosteroids

For decades, systemic corticosteroids have been used and considered as the gold standard for treatment of the disease, especially for generalized BP [1, 2, 31, 134, 137, 143–145],

Table 3 Therapeutic options for the treatment of BP

Treatment	Level of evidence ^a	Mechanism of action in BP
Superpotent topical corticosteroids	1	Anti-inflammatory
Oral corticosteroids (prednisone 0.5–1 mg/kg/day)	1	Anti-inflammatory or immunosuppressive ^b
Azathioprine	1	Immunosuppressive
Mycophenolate mofetil	1	Immunosuppressive
Methotrexate	2	Anti-inflammatory or immunomodulatory
Chlorambucil	3	Immunosuppressive
Cyclophosphamide	3	Immunosuppressive
Tetracyclines + nicotinamide	2	Anti-inflammatory
Dapsone	3	Anti-inflammatory
Intravenous immunoglobulin	3	Immunomodulatory
Plasmapheresis ^c	1	Removal of autoantibodies
Immunoabsorption	3	Removal of autoantibodies
Rituximab	3	Removal of B lymphocytes
Omalizumab	3	Blockage of IgE autoantibodies

BP bullous pemphigoid, IgE immunoglobulin E

^a Key to evidence-based support: (1) large, randomized prospective study; (2) small randomized study (prospective or retrospective) or large retrospective case series; (3) small case series or case reports

^b Depending on the dose

^c Currently abandoned

and their efficacy has been established in controlled studies [80, 134, 135, 137]. In patients with extensive disease, defined by some authors as either the occurrence of more than 10 new blisters per day [80, 81] or the presence of inflammatory lesions covering a large body surface area [140], oral prednisone at the dosage of 0.5–1 mg/kg/day represents the most endorsed treatment and usually controls the disease within 1 or 2 weeks. This dose is then progressively tapered down over a period of 6–9 months, or occasionally longer [34, 144]; however, the use of systemic corticosteroids in the elderly is associated with significant side effects [80, 131, 136]. In particular, a high dose of systemic corticosteroids, such as prednisone 1 mg/kg/day, has been associated with higher mortality and increased adverse events compared with whole-body topical use of clobetasol propionate 0.05% [80, 141]. A medium dose of systemic corticosteroids, such as prednisone 0.5 mg/kg/day, is effective in moderate disease [80] and is suggested by some authors in extensive disease despite the lack of evidence [144]. Dosages of prednisone under 0.5 mg/kg/day seem ineffective [135]. Occasionally, pulse therapy with methylprednisolone may be required for rapid control of the disease.

Based on two randomized controlled studies and one retrospective study, which included a total of close to 800 patients with BP [80, 81, 146], potent topical corticosteroid

therapy is the most effective treatment during the acute phase of BP [132], and now represents the first therapeutic option whenever possible. Potent topical corticosteroids such as clobetasol propionate 0.05% cream control extensive BP with the same efficacy as oral corticosteroids, but with fewer systemic side effects and reduced mortality [80]. Clobetasol propionate ointment, initially 40 g daily for 1 month, with subsequent slow reduction over the following 12 months, is even better than oral prednisone (0.5 mg/day) in the time needed to control the disease [80]. Besides, dosages of 10–30 g/day may usually be sufficient to control the disease, with rapid tapering and cessation of therapy within 4 months [81]. Indeed, more than 95% of patients with BP achieved disease control after a mean delay of 7–15 days after therapy initiation [80, 81]. However, this treatment is not always feasible and its long-term efficacy is questionable because of the significant corticosteroid-induced skin atrophy and practical difficulties in the management of elderly patients. Indeed, a recent study showed that patients with poor compliance had a more than fourfold increased risk of relapse compared with patients who had good compliance with potent topical corticosteroid therapy [147]. In localized or mild disease with few non-bullous inflammatory or localized lesions involving only one body site, potent topical corticosteroids again represent the first therapeutic option [132, 142, 144].

5.2 Immunosuppressive Drugs

Immunosuppressive therapy with corticosteroid-sparing effects should be considered a second-line therapy when corticosteroids alone fail to control the disease, or in cases of contraindications to oral corticosteroids and comorbidities (such as diabetes, severe osteoporosis, cardiovascular disorders) [141–144]. Nevertheless, there is currently no positive evidence supporting their use as first-line therapy [132, 141, 144]. The choice of a particular immunosuppressive drug depends on its side-effect profile, the overall conditions of the patient, and the experience of the physician. The immunosuppressive drugs that may be used for the treatment of BP are azathioprine, mycophenolate mofetil, methotrexate, chlorambucil and cyclophosphamide [65, 132, 141, 144]. Based on the current lack of evidence for its efficacy and the potential adverse event profile, including nephrotoxicity in elderly patients, the use of ciclosporin is not recommended [144]. Azathioprine is the best characterized first-line immunosuppressive and corticosteroid-sparing drug for the treatment of BP [133, 136, 140]. The recommended dosage of azathioprine (1–3 mg/kg/day orally) [144] must be adjusted according to the level of thiopurine methyltransferase in order to increase efficacy and reduce toxicity [148]. Because of its better safety profile, mycophenolate mofetil (1.5–2 g/day orally) is gradually replacing azathioprine as the antimetabolite adjuvant of choice in the treatment of many autoimmune diseases, including BP [70, 140]. Although retrospective, several reports have suggested that low-dose methotrexate (up to 15 mg once a week orally, subcutaneously, or intramuscularly) should be effective in BP in combination with oral or topical corticosteroids [149–152]. A recent retrospective study showed that low-dose methotrexate combined with short-term potent topical corticosteroid therapy may result in long-term control of BP, with 77% of patients achieving a protracted complete clinical remission of their disease [152]. This study confirmed the interest of this therapeutic regimen in BP with a satisfying benefit/risk ratio with respect to its ability to maintain the initial complete clinical remission obtained by topical corticosteroids, its overall good tolerance pattern and its easy-to-use administration [152]. In this setting, the results of a nationwide, randomized controlled trial conducted in France comparing initial potent topical corticosteroids and methotrexate versus potent topical corticosteroids alone are currently being analyzed. Small series or case reports have reported success with chlorambucil (0.1 mg/kg/day, frequently 2–4 mg/day orally) or cyclophosphamide (1–3 mg/kg/day) as corticosteroid-sparing adjuvants in cases of generally severe or refractory BP [153, 154]. However, the additional benefit of

cyclophosphamide is balanced by its great toxic effects, particularly in those elderly patients affected with BP [65].

5.3 Antimicrobials and Dapsone

The combination of nicotinamide (500–2500 mg/day orally) and tetracyclines (oxytetracycline 2 g/day orally) or doxycycline (200 mg/day orally) has been tried with some success in small series and may serve as a therapeutic alternative, in association with topical corticosteroids, when obvious contraindications to systemic corticosteroids exist [65, 138]. A multinational, prospective, randomized trial comparing the safety and effectiveness of doxycycline (200 mg/day) with oral prednisolone (0.5 mg/kg/day) for the initial treatment of BP is currently being analyzed [155]. Unless glucose-6-phosphate dehydrogenase deficiency is evident, the use of dapsone (up to 1.5 mg/kg/day orally) may also be warranted, generally in association with topical or systemic corticosteroids, especially in the presence of mucosal involvement [143, 144, 156, 157]. However, the side-effect profile of dapsone is potentially hazardous in elderly patients, with frequent dose-dependent anemia and infrequent hypersensitivity syndrome [65, 143].

5.4 Immunomodulatory Therapy and Biologics

Topical immunomodulators, such as tacrolimus ointment, have been proposed, either alone or in association with systemic agents, for the treatment of localized or generalized forms of BP [158, 159]. It is likely that tacrolimus represents an alternative to topical corticosteroids in mild disease without the disadvantage of causing skin atrophy. Nevertheless, its use is limited by its price [34, 143]. In small retrospective studies and case reports, high-dose intravenous IG has been used for treating BP, more commonly as monthly cycles in association with oral corticosteroids and other agents [160–162]. This expensive treatment should be considered as an adjunctive treatment in patients with severe and refractory disease, or in case of contraindication to other systemic agents [143]. In the 1980s, plasmapheresis was used as adjuvant treatment for corticosteroid-resistant BP, with varied results [135, 136, 163]. Immunoabsorption (immunoapheresis) is currently replacing plasmapheresis treatment, but there are only a few case reports for its use as adjuvant treatment for severe and resistant cases [164].

To date, only a few reported cases of BP have been treated with biologic agents, including the anti-CD20 agent rituximab [165–168] and the TNF α antagonist etanercept [169]. Most reported cases had severe and refractory disease and were treated concomitantly with corticosteroids or

other immunosuppressants. In the majority of reported cases, rituximab treatment allowed progressive withdrawal of corticosteroids or other immunosuppressants, although disease outcome was variable and serious side effects were observed, including death [165–168]. The combination of rituximab and intravenous IG produced a sustained clinical remission without adverse events in patients with recalcitrant BP [170]. On the basis of the possible pathogenicity of anti-BP180 IgE autoantibodies, omalizumab, a monoclonal antibody that inhibits IgE binding, was used with success in treatment-refractory cases of BP [171, 172].

TNF antagonists such as etanercept or adalimumab have been reported as inducing factors of BP in some cases [173]. In contrast, etanercept was used successfully to treat a patient with both BP and psoriasis [169]. Further studies are necessary to determine whether TNF antagonists could represent a potential therapy for BP. Finally, BP is an inflammatory autoimmune bullous disease involving cytokines and proteases in the process of blister formation, with large amounts of IL-23 and IL-17 in lesional skin and serum of BP patients at the time of diagnosis [73]. Moreover, IL-23 serum concentrations increased or remained elevated during the first month of treatment in BP patients who later relapsed [174], and we recently observed a case of BP associated with psoriasis in which both diseases were totally controlled under ustekinumab as single therapy [175]. However, paradoxical effects with this molecule are possible, as suggested by a recent case of BP occurring during the treatment of psoriatic arthritis with ustekinumab [176]. Thus, additional observations or proof-of-concept studies are necessary to demonstrate that biologics targeting components of the IL-23/IL-17 cascade could be an alternative for severe, treatment-refractory BP with a better satisfactory benefit/risk ratio than immunosuppressants or methotrexate, which display a number of side effects or contraindications in those fragile, elderly patients.

5.5 Monitoring

For clinical monitoring, it is now recommended the definitions and outcome measures specific for BP be used to assess disease severity and therapeutic response [78]. For biological monitoring, the practical use of serological test results, such as ELISA-BP180, as a means of guiding treatment remains to be established. Indeed, the serum concentration of IgG autoantibodies to BP180 correlated with disease severity in ELISA-based studies [5, 7, 59, 84], and its fluctuations between days 0, 60, and 150 may predict outcome [86, 177]. In this setting, a small decrease in anti-BP180 IgG serum levels between days 0 and 60 is a factor associated with disease relapse within the first year of treatment [86]. Finally, a high BP180-NC16A ELISA titer and positive direct IF findings at the cessation of

therapy are both good indicators of later relapse of BP [85, 178].

6 Conclusions

Our scientific knowledge of BP, the main autoimmune bullous disorder, has dramatically increased in recent years. However, overall mortality is significantly increased in BP, which can be attributed to either comorbidities or immunosuppressive therapy. Current therapeutic management of BP relies on some certainties. Potent topical corticosteroids have emerged as an effective and safe first-line treatment for BP but their long-term feasibility is still controversial. On the other hand, high doses of oral prednisone are deleterious and the exact place of immunosuppressive drugs remains to be defined. Newer therapeutic agents targeting molecules involved in the inflammatory cascade associated with BP represent future alternatives to corticosteroids or classical immunosuppressant drugs for maintenance therapy. Biologics selectively suppressing autoantibody formation, inflammation cascade, or both, are available and could represent a new therapeutic horizon for BP.

Compliance with Ethical Standards

Funding No funding was received for the preparation of this review.

Conflict of interest Philippe Bernard and Frank Antonicelli have no conflicts of interest to declare.

References

1. Stanley JR. Pemphigus and pemphigoid as paradigms of organ-specific, autoantibody-mediated diseases. *J Clin Invest.* 1989;83:1443–8.
2. Schmidt E, Zillikens D. Pemphigoid diseases. *Lancet.* 2013;381:320–32.
3. Stanley JR, Tanaka T, Mueller S, et al. Isolation of complementary DNA for bullous pemphigoid antigen by use of patients' autoantibodies. *J Clin Invest.* 1988;82:1864–70.
4. Giudice GJ, Emery DJ, Diaz LA. Cloning and primary structural analysis of the bullous pemphigoid autoantigen BP180. *J Invest Dermatol.* 1992;99:243–50.
5. Zillikens D, Rose PA, Balding SD, et al. Tight clustering of extracellular BP180 epitopes recognized by bullous pemphigoid autoantibodies. *J Invest Dermatol.* 1997;109:573–9.
6. Thoma-Uszynski S, Uter W, Schwietzke S, et al. Autoreactive T and B cells from bullous pemphigoid (BP) patients recognize epitopes clustered in distinct regions of BP180 and BP230. *J Immunol.* 2006;176:2015–23.
7. Di Zenzo G, Thoma-Uszynski S, Fontao L, et al. Multicenter prospective study of the humoral autoimmune response in bullous pemphigoid. *Clin Immunol.* 2008;128:415–26.
8. Giudice GJ, Wilske KC, Anhalt GJ, et al. Development of an ELISA to detect anti-BP180 autoantibodies in bullous

- pemphigoid and herpes gestationis. *J Invest Dermatol.* 1994;102:878–81.
9. Zillikens D, Mascaro JM, Rose PA, Liu Z, Ewing SM, Caux F, et al. A highly sensitive enzyme-linked immunosorbent assay for the detection of circulating anti-BP180 autoantibodies in patients with bullous pemphigoid. *J Invest Dermatol.* 1997;109:679–83.
 10. Kobayashi M, Amagai M, Kuroda-Kinoshita K, et al. BP180 ELISA using bacterial recombinant NC16a protein as a diagnostic and monitoring tool for bullous pemphigoid. *J Dermatol Sci.* 2002;30:224–32.
 11. Di Zenzo G, Grosso F, Terracina M, et al. Characterization of the anti-BP180 autoantibody reactivity profile and epitope mapping in bullous pemphigoid patients. *J Invest Dermatol.* 2004;122:103–10.
 12. Sakuma-Oyama Y, Powell AM, et al. Evaluation of a BP180-NC16a enzyme-linked immunosorbent assay in the initial diagnosis of bullous pemphigoid. *Br J Dermatol.* 2004;151:126–31.
 13. Thoma-Uszynski S, Uter W, Schwietzke S, et al. BP230- and BP180-specific auto-antibodies in bullous pemphigoid. *J Invest Dermatol.* 2004;122:1413–22.
 14. Tsuji-Abe Y, Akiyama M, Yamanaka Y, et al. Correlation of clinical severity and ELISA indices for the NC16A domain of BP180 measured using BP180 ELISA kit in bullous pemphigoid. *J Dermatol Sci.* 2005;37:145–9.
 15. Di Zenzo G, Thoma-Uszynski S, Calabresi V, et al. Demonstration of epitope-spreading phenomena in bullous pemphigoid: results of a prospective multicenter study. *J Invest Dermatol.* 2011;131:2271–80.
 16. Charneux J, Lorin J, Vitry F, et al. Usefulness of BP230 and BP180-NC16a enzyme-linked immunosorbent assays in the initial diagnosis of bullous pemphigoid: a retrospective study of 138 patients. *Arch Dermatol.* 2011;147:286–91.
 17. Gammon WR, Merritt CC, Lewis DM, et al. An in vitro model of immune complex-mediated basement membrane zone separation caused by pemphigoid antibodies, leukocytes, and complement. *J Invest Dermatol.* 1982;78:285–90.
 18. Sitaru C, Schmidt E, Petermann S, et al. Autoantibodies to bullous pemphigoid antigen 180 induce dermal-epidermal separation in cryosections of human skin. *J Invest Dermatol.* 2002;118:664–71.
 19. Liu Z, Diaz LA, Troy JL, et al. A passive transfer model of the organ-specific autoimmune disease, bullous pemphigoid, using antibodies generated against the hemidesmosomal antigen, BP180. *J Clin Invest.* 1993;92:2480–8.
 20. Nishie W, Sawamura D, Goto M, et al. Humanization of autoantigen. *Nat Med.* 2007;13:378–83.
 21. Ujiie H, Shibaki A, Nishie W, et al. A novel active mouse model for bullous pemphigoid targeting humanized pathogenic antigen. *J Immunol.* 2010;184:2166–74.
 22. Bernard P, Vaillant L, Labeille B, et al. Incidence and distribution of subepidermal autoimmune bullous skin diseases in three French regions. Bullous Diseases French Study Group. *Arch Dermatol.* 1995;131:48–52.
 23. Zillikens D, Wever S, Roth A, et al. Incidence of autoimmune subepidermal blistering dermatoses in a region of central Germany. *Arch Dermatol.* 2005;131:957–8.
 24. Jung M, Kippes W, Messer G, et al. Increased risk of bullous pemphigoid in male and very old patients: a population-based study on incidence. *J Am Acad Dermatol.* 1999;41:266–8.
 25. Gudi VS, White MI, Cruikshank N, et al. Annual incidence and mortality of bullous pemphigoid in the Grampian region of north-east Scotland. *Br J Dermatol.* 2005;153:424–7.
 26. Langan SM, Smeeth L, Hubbard R, et al. Bullous pemphigoid and pemphigus vulgaris incidence and mortality in the UK: population based cohort study. *BMJ.* 2008;337:a180.
 27. Marazza G, Pham HC, Schärer L, et al. Incidence of bullous pemphigoid and pemphigus in Switzerland: a 2-year prospective study. *Br J Dermatol.* 2009;161:861–8.
 28. Joly P, Baricault S, Sparsa A, et al. Incidence and mortality of bullous pemphigoid in France. *J Invest Dermatol.* 2012;132:1998–2004.
 29. Brick K, Weaver C, Lohse CM, et al. Incidence of bullous pemphigoid and mortality of patients with bullous pemphigoid in Olmsted County, Minnesota, 1960 through 2009. *J Am Acad Dermatol.* 2014;71:92–9.
 30. Försti AK, Jokelainen J, Timonen M, Tasanen K. Increasing incidence of bullous pemphigoid in Northern Finland: a retrospective study database study in Oulu University Hospital. *Br J Dermatol.* 2014;171:1223–6.
 31. Korman N. Bullous pemphigoid. *J Am Acad Dermatol.* 1987;16:907–24.
 32. Waisbourd-Zinman O, Ben-Ami D, Cohen AD, et al. Bullous pemphigoid in infancy: clinical and epidemiologic characteristics. *J Am Acad Dermatol.* 2008;58:41–8.
 33. Schweiger-Briel A, Moellmann C, Mattulat B, et al. Bullous pemphigoid in infants: characteristics, diagnosis and treatment. *Orphanet J Rare Dis.* 2014;9:185.
 34. Di Zenzo G, Marazza G, Borradori L. Bullous pemphigoid: physiopathology, clinical features and management. *Adv Dermatol.* 2007;23:257–88.
 35. Schmidt E, Benoit S, Brocker EB. Bullous pemphigoid with localized umbilical involvement. *Acta Derm Venereol.* 2009;89:419–20.
 36. Callens A, Vaillant L, Machet MC, et al. Localized atypical pemphigoid on lymphedema following radiotherapy. *Acta Derm Venereol.* 1993;73:461–4.
 37. Borradori L, Prost C, Woklenstein P, et al. Localized pretibial bullous pemphigoid and pemphigoid nodularis: report of a case. *J Am Acad Dermatol.* 1992;27:863–7.
 38. Descamps V, Flageul B, Vignon-Pennamen D, et al. Dyshidrosiform pemphigoid: report of three cases. *J Am Acad Dermatol.* 1992;26:651–2.
 39. Farrell AM, Kirtschig G, Dalziel KL, et al. Childhood vulvar pemphigoid: a clinical and immunopathological study of five patients. *Br J Dermatol.* 1999;140:308–12.
 40. Komine M, Nashiro K, Asahina K, et al. Vesicular pemphigoid. *Int J Dermatol.* 1992;31:868–70.
 41. Delpuget-Martin N, Bernard P, Bedane C, et al. Pemphigoïde végétante. *Ann Dermatol Vénéreol.* 1997;124:467–9.
 42. Cliff S, Holden CA. Pemphigoid nodularis: a report of three cases and review of the literature. *Br J Dermatol.* 1997;136:398–401.
 43. Korman NJ, Woods SG. Erythrodermic bullous pemphigoid is a clinical variant of bullous pemphigoid. *Br J Dermatol.* 1995;133:967–71.
 44. Cordel N, Courville P, Martel P, et al. Extensive erosive bullous pemphigoid: an atypical and serious clinical variant. *Br J Dermatol.* 2002;146:537–9.
 45. Cordel N, Chosidow O, Hellot M-F, et al. Neurological disorders in patients with bullous pemphigoid. *Dermatology.* 2007;215:187–91.
 46. Stinco G, Codutti R, Scarbolo M, Valent F, Patrone P. A retrospective epidemiological study on the association of bullous pemphigoid and neurological diseases. *Acta Derm Venereol.* 2005;85:136–9.
 47. Chosidow O, Doppler V, Bensimon G, et al. Bullous pemphigoid and amyotrophic lateral sclerosis: a new clue for understanding the bullous disease? *Arch Dermatol.* 2000;136:521–4.
 48. Jedlickova H, Hlubinka M, Pavlik T, et al. Bullous pemphigoid and internal diseases: a case-control study. *Eur J Dermatol.* 2010;20:96–101.

49. Taghipour K, Chi C-C, Vincent A, Groves RW, Venning V, Wojnarowska F. The association of bullous pemphigoid with cerebrovascular disease and dementia: a case-control study. *Arch Dermatol*. 2010;146:1251-4.
50. Chen YJ, Wu CY, Lin MW, Chen TJ, Liao KK, Chen YC, et al. Comorbidity profiles among patients with bullous pemphigoid: a nationwide population-based study. *Br J Dermatol*. 2011;165:593-9.
51. Langan SM, Groves RW, West J. The relationship between neurological disease and bullous pemphigoid: a population-based case-control study. *J Invest Dermatol*. 2011;131:631-6.
52. Bastuji-Garin S, Joly P, Lemordant P, et al. Risk factors for bullous pemphigoid in the elderly. A prospective case-control study. *J Invest Dermatol*. 2011;131:637-43.
53. Brick K, Weaver CH, Savica R, et al. A population-based study of the association between bullous pemphigoid and neurologic disorders. *J Am Acad Dermatol*. 2014;71:1191-7.
54. Casas-de-la-Asuncion E, Ruano-Ruiz J, Rodriguez-Martin AM, et al. Association between bullous pemphigoid and neurologic diseases: a case-control study in Portuguese patients. *Actas Dermosifiliogr*. 2014;105:860-5.
55. Texeira VB, Cabral R, Brites MM, et al. Bullous pemphigoid and comorbidities: a case-control study in Portuguese patients. *An Bras Dermatol*. 2014;89:274-9.
56. Chevalier V, Barbe C, Reguiat Z, et al. Impact of neurological diseases on the prognosis of bullous pemphigoid: a retrospective study of 178 patients [in French]. *Ann Dermatol Vénéréol*. 2016;143:179-86.
57. Lai YC, Yew YW, Lambert WC. Bullous pemphigoid and its association with neurological diseases: a systematic review and meta-analysis. *J Eur Acad Dermatol Venereol*. 2016;30:2007-15.
58. Seppanen A, Suuronen T, Hofmann SC, et al. Distribution of collagen XVII in the human brain. *Brain Res*. 2007;1158:50-6.
59. Di Zeno G, Della Torre R, Zambruno G, Borradori L. Bullous pemphigoid: from the clinic to the bench. *Clin Dermatol*. 2012;30:3-16.
60. Vassilieva S. Drug-induced pemphigoid: bullous and cicatricial. *Clin Dermatol*. 1998;16:379-87.
61. Stravopoulos PG, Soura E, Antoniou C. Drug-induced pemphigoid. *J Eur Acad Dermatol*. 2014;28:1133-40.
62. Bastuji-Garin S, Joly P, Picard-Dahan C, et al. Drugs associated with bullous pemphigoid. A case-control study. *Arch Dermatol*. 1996;132:272-6.
63. Lloyd-Lavery A, Chi CC, Wojnarowska F, Taghipour K. The associations between bullous pemphigoid and drug use: a UK case-control study. *JAMA Dermatol*. 2013;149:58-62.
64. Bene J, Moulis G, Bennani I, et al. Bullous pemphigoid and dipeptidyl peptidase IV inhibitors: a case-noncase study in the French Pharmacovigilance database. *Br J Dermatol*. 2016;175(2):296-301.
65. Ruocco E, Wolf R, Caccavale S, et al. Bullous pemphigoid: associations and management guidelines: facts and controversies. *Clin Dermatol*. 2013;31:400-12.
66. Venning VA, Wojnarowska F. The association between and malignant disease: a case-control study. *Br J Dermatol*. 1990;123:439-45.
67. Lindelof B, Islam N, Eklund G, et al. Pemphigoid and cancer. *Arch Dermatol*. 1990;126:66-8.
68. Ogawa H, Sakuma M, Morioka S, et al. The incidence of internal malignancies in pemphigus and bullous pemphigoid in Japan. *J Dermatol Sci*. 1995;9:136-41.
69. Ong E, Goldacre R, Hoang U, et al. Associations between bullous pemphigoid and primary malignant cancers: an English national record linkage study, 1999-2011. *Arch Dermatol Res*. 2014;306:75-80.
70. Schulze F, Neumann K, Recke A, et al. Malignancies in pemphigus and pemphigoid diseases. *J Invest Dermatol*. 2015;135:1445-7.
71. Kirtschig G, Chow ET, Venning VA, et al. Acquired subepidermal bullous diseases associated with psoriasis: a clinical, immunopathological and immunogenetic study. *Br J Dermatol*. 1996;135:738-45.
72. Wilczek A, Sticherling M. Concomitant psoriasis and bullous pemphigoid: coincidence or pathogenic relationship? *Int J Dermatol*. 2006;45:1353-7.
73. Le Jan S, Plée J, Vallerand D, et al. Innate immune cell-produced IL-17 sustains inflammation in bullous pemphigoid. *J Invest Dermatol*. 2014;134:2908-17.
74. Shipman AR, Cooper S, Wojnarowska F. Autoreactivity to bullous pemphigoid 180: is this the link between subepidermal blistering diseases and oral lichen planus? *Clin Exp Dermatol*. 2011;36:267-9.
75. Taylor G, Venning V, Wojnarowska F, et al. Bullous pemphigoid and autoimmunity. *J Am Acad Dermatol*. 1993;29:181-4.
76. Chuang TY, Korkij W, Soltani K, et al. Increased frequency of diabetes mellitus in patients with bullous pemphigoid: a case-control study. *J Am Acad Dermatol*. 1984;11:1099-102.
77. Oh DD, Zhao CY, Murrell DF. A review of case-control studies on the risk factors for the development of auto-immune blistering diseases. *J Eur Acad Dermatol*. 2016;30:595-603.
78. Murrell DF, Daniel BS, Joly P, et al. Definitions and outcome measures for bullous pemphigoid: recommendations by an international panel of experts. *J Am Acad Dermatol*. 2012;66:479-85.
79. Levy-Sitbon C, Barbe C, Plee J, et al. Assessment of bullous pemphigoid disease area index during treatment: a prospective study of 30 patients. *Dermatology*. 2014;229:116-22.
80. Joly P, Roujeau JC, Benichou J, et al. A comparison of oral and topical corticosteroids in patients with bullous pemphigoid. *N Engl J Med*. 2002;346:321-7.
81. Joly P, Roujeau JC, Benichou J, et al. A comparison of two regimens of topical corticosteroids in the treatment of patients with bullous pemphigoid: a multicenter randomized study. *J Invest Dermatol*. 2009;129:1681-7.
82. Vaillant L, Bernard P, Joly P, et al. Evaluation of clinical criteria for diagnosis of bullous pemphigoid. *Arch Dermatol*. 1998;134:1075-80.
83. Joly P, Courville P, Lok C, et al. Clinical criteria for the diagnosis of bullous pemphigoid: a reevaluation according to immunoblot analysis of patient sera. *Dermatology*. 2004;208:16-20.
84. Joly P, Benichou J, Lok C, et al. Prediction of survival for patients with bullous pemphigoid: a prospective study. *Arch Dermatol*. 2005;141:691-8.
85. Bernard P, Reguiat Z, Tancrede-Bohin E, et al. Risk factors for relapse in patients with bullous pemphigoid in clinical remission: a multicenter, prospective, cohort study. *Arch Dermatol*. 2009;145:537-42.
86. Fichel F, Barbe C, Joly P, et al. Clinical and immunologic factors associated with bullous pemphigoid relapse during the first year of treatment: a multicenter, prospective study. *JAMA Dermatol*. 2014;150:25-33.
87. della Torre R, Combesure C, Cortes B, et al. Clinical presentation and diagnostic delay in bullous pemphigoid: a prospective nationwide cohort. *Br J Dermatol*. 2012;167:1111-7.
88. Lipsker D, Borradori L. Bullous pemphigoid: what are you? Urgent need of definitions and diagnostic criteria. *Dermatology*. 2010;221:131-4.
89. Schmidt E, della Torre R, Borradori L. Clinical features and practical diagnosis of bullous pemphigoid. *Clin Dermatol*. 2011;29:427-38.

90. Gammon WR, Kowalewski C, Chorzelski TP, et al. Direct immunofluorescence studies of sodium chloride-separated skin in the differential diagnosis of bullous pemphigoid and epidermolysis bullosa acquisita. *J Am Acad Dermatol.* 1990;22:664–70.
91. Terra JB, Meijer JM, Jonkman MF, Diercks GFH. The n- vs. u-serration is a learnable criterion to differentiate pemphigoid from epidermolysis bullosa acquisita in direct immunofluorescence serration-pattern analysis. *Br J Dermatol.* 2013;169:100–5.
92. De Jong MC, Bruins S, Heeres K, et al. Bullous pemphigoid and epidermolysis bullosa acquisita. Differentiation by fluorescence overlay antigen mapping. *Arch Dermatol.* 1996;132:151–7.
93. Kelly SE, Wojnarowska F. The use of chemically split tissue in the detection of circulating anti-basement membrane zone antibodies in bullous pemphigoid and cicatricial pemphigoid. *Br J Dermatol.* 1988;118:31–40.
94. Gammon WR, Fine JD, Forbes M, et al. Immunofluorescence on split skin for the detection and differentiation of basement membrane zone autoantibodies. *J Am Acad Dermatol.* 1992;27:79–87.
95. Sardy M, Kostaki D, Varga R, et al. Comparative study of direct and indirect immunofluorescence and of bullous pemphigoid 180 and 230 enzyme-linked immunosorbent assays for diagnosis of bullous pemphigoid. *J Am Acad Dermatol.* 2013;69:748–53.
96. van Beek N, Rentsch K, Probst C, et al. Serological diagnosis of autoimmune bullous skin diseases: prospective comparison of the BIOCHIP mosaic-based indirect immunofluorescence technique with the conventional multi-step single test strategy. *Orphanet J Rare Dis.* 2012;7:49.
97. Labib RS, Anhalt GJ, Patel HP, et al. Molecular heterogeneity of the bullous pemphigoid antigens as detected by immunoblotting. *J Immunol.* 1986;136:1231–5.
98. Bernard P, Didierjean L, Denis F, et al. Heterogeneous bullous pemphigoid antibodies : detection and characterization by immunoblotting when absent by indirect immunofluorescence. *J Invest Dermatol.* 1989;92:171–5.
99. Bernard P, Aucouturier P, Denis F, et al. Immunoblot analysis of IgG subclasses of circulating antibodies in bullous pemphigoid. *Clin Immunol Immunopathol.* 1990;54:484–94.
100. Gohestani R, Kanitakis J, Nicolas JF, et al. Comparative sensitivity of indirect immunofluorescence to immunoblot assay for the detection of circulating antibodies to bullous pemphigoid antigens 1 and 2. *Br J Dermatol.* 1996;135:74–9.
101. Barnadas MA, Rubiales MV, González MJ, et al. Enzyme-linked immunosorbent assay (ELISA) and indirect immunofluorescence testing in a bullous pemphigoid and pemphigoid gestationis. *Int J Dermatol.* 2008;47:1245–9.
102. Schmidt E, Obe K, Bröcker EB, Zillikens D. Serum levels of autoantibodies to BP180 correlate with disease activity in patients with bullous pemphigoid. *Arch Dermatol.* 2000;136:174–8.
103. Roussel A, Benichou J, Randriamanantany ZA, et al. Enzyme-linked immunosorbent assay for the combination of bullous pemphigoid antigens 1 and 2 in the diagnosis of bullous pemphigoid. *Arch Dermatol.* 2011;147:293–8.
104. Kromminga A, Sitaru C, Hagel C, et al. Development of an ELISA for the detection of autoantibodies to BP230. *Clin Immunol.* 2004;111:146–52.
105. Tampoia M, Lattanzi V, Zucano A, et al. Evaluation of a new ELISA assay for detection of BP230 autoantibodies in bullous pemphigoid. *Ann N Y Acad Sci.* 2009;1173:15–20.
106. Le Saché-de Peufeilhoux L, Ingen-Housz-Oro S, Hue S, et al. The value of BP230 enzyme-linked immunosorbent assay in the diagnosis and immunological follow-up of bullous pemphigoid. *Dermatology.* 2012;224:154–9.
107. Wieland CN, Confere NI, Gibson LE, et al. Anti-bullous pemphigoid 180 and 230 antibodies in a sample of unaffected subjects. *Arch Dermatol.* 2010;146:21–5.
108. van Beek N, Dohse A, Riechert F, et al. Serum autoantibodies against the dermal-epidermal junction in patients with chronic pruritic disorders, elderly individuals and blood donors prospectively recruited. *Br J Dermatol.* 2014;170:943–7.
109. Meijer JM, Lamberts A, Pas HH, Jonkman MF. Significantly higher prevalence of circulating bullous pemphigoid-specific IgG autoantibodies in elderly patients with a non-bullous skin disorder. *Br J Dermatol.* 2015;173:1274–6.
110. Bernard P, Antonicelli F, Bedane C, et al. Prevalence and clinical significance of anti-Laminin 332 autoantibodies detected by a novel enzyme-linked immunosorbent assay in mucous membrane pemphigoid. *JAMA Dermatol.* 2013;149:533–40.
111. Chan LS, Ahmed AR, Anhalt GJ, et al. The first international consensus on mucous membrane pemphigoid: definition, diagnostic criteria, pathogenic factors, medical treatment, and prognostic indicators. *Arch Dermatol.* 2002;138:370–9.
112. Ghohestani RF, Nicolas JF, Rousselle P, Claudy AL. Diagnostic value of indirect immunofluorescence on sodium chloride-split skin in differential diagnosis of subepidermal autoimmune bullous dermatoses. *Arch Dermatol.* 1997;133:1102–7.
113. Schmidt E, Skrobek C, Kromminga A, et al. Cicatricial pemphigoid: IgA and IgG autoantibodies target epitopes on both intra- and extracellular domains of bullous pemphigoid antigen 180. *Br J Dermatol.* 2001;145:778–83.
114. Yeh SW, Usman AQ, Ahmed AR. Profile of autoantibody to basement membrane zone proteins in patients with mucous membrane pemphigoid: long-term follow up and influence of therapy. *Clin Immunol.* 2004;112:268–72.
115. Oyama N, Setterfield JF, Powell AM, et al. Bullous pemphigoid antigen II (BP180) and its soluble extracellular domains are major autoantigens in mucous membrane pemphigoid: the pathogenic relevance to HLA class II alleles and disease severity. *Br J Dermatol.* 2006;154:90–8.
116. Bruch-Gerharz D, Hertl M, Ruzicka T. Mucous membrane pemphigoid: clinical aspects, immunopathological features and therapy. *Eur J Dermatol.* 2007;17:191–200.
117. Ludwig R. Clinical presentation, pathogenesis, diagnosis, and treatment of epidermolysis bullosa acquisita. *ISRN Dermatol.* 2013;2013:812029.
118. Chen M, Kim GH, Prakash I, Woodley DT. Epidermolysis bullosa acquisita: autoimmunity against to anchoring fibril collagen. *Autoimmunity.* 2012;45:91–101.
119. Komorowski L, Müller R, Vorobyev A. Sensitive and specific assays for routine serological diagnosis of epidermolysis bullosa acquisita. *J Am Acad Dermatol.* 2013;68:e89–95.
120. Yaoita H, Briggaman RA, Lawley TH. Epidermolysis bullosa acquisita : ultrastructural and immunological studies. *J Invest Dermatol.* 1981;76:288–92.
121. Dainichi T, Koga H, Tsuji T, et al. From anti-P200 pemphigoid to anti laminin gamma1 pemphigoid. *J Dermatol.* 2010;37:231–8.
122. Groth S, Recke A, Vafia K, et al. Development of a simple ELISA for the detection of autoantibodies in anti-P200 pemphigoid. *Br J Dermatol.* 2011;164:76–82.
123. Danichi T, Kurono S, Ohyama B, et al. Anti-laminin gamma-1 pemphigoid. *Proc Natl Acad Sci USA.* 2009;106:2800–5.
124. Rieckhoff-Cantoni L, Bernard P, Didierjean L, et al. Frequency of bullous pemphigoid-like antibodies as detected by western blotting in pruritic dermatoses. *Arch Dermatol.* 1992;128:791–4.
125. Baaker C, Terra JB, Jonkman MF. Bullous pemphigoid as pruritus in the elderly. A common presentation. *JAMA Dermatol.* 2014;149:950–3.

126. Kyriakis KP, Pappas VA, Panteleos DN, Tosca AD. Re-evaluation of the natural course of bullous pemphigoid. A prospective study. *Int J Dermatol*. 1999;38:909–13.
127. Bernard P, Bedane C, Bonnetblanc JM. Anti-BP180 autoantibodies as a marker of poor vital prognosis in bullous pemphigoid: a cohort analysis of 94 elderly patients. *Br J Dermatol*. 1997;136:694–8.
128. Colbert RL, Allen DM, Eastwood D, et al. Mortality rate of bullous pemphigoid in a US medical center. *J Invest Dermatol*. 2004;122:1091–5.
129. Cortés B, Khelifa E, Clivaz L, et al. Mortality rate in bullous pemphigoid: a retrospective monocentric cohort study. *Dermatology*. 2012;225:320–5.
130. Roujeau JC, Lok C, Bastuji-Garin S, et al. High risk of death in elderly patients with extensive bullous pemphigoid. *Arch Dermatol*. 1998;134:465–9.
131. Rzyan B, Partscht K, Jung M, et al. Risk factors for lethal outcome inpatients with bullous pemphigoid: low serum albumin level, high dosage of glucocorticosteroids, and old age. *Arch Dermatol*. 2002;138:903–8.
132. Kirtschig G, Middleton P, Bennett C, et al. Interventions for bullous pemphigoid. *Cochrane Database Syst Rev*. 2010;(10):CD002292.
133. Burton JL, Harman RM, Peachey RD, et al. A controlled trial of azathioprine in the treatment of pemphigoid [proceedings]. *Br J Dermatol*. 1978;99:14.
134. Morel P, Guillaume JC. Treatment of bullous pemphigoid with prednisolone only: 0.75 mg/kg/day versus 1.25 mg/kg/day. A multicenter randomized study. *Ann Dermatol Venereol*. 1984;111:925–8.
135. Roujeau JC, Guillaume JC, Morel P, et al. Plasma exchange in bullous pemphigoid. *Lancet*. 1984;2:486–8.
136. Guillaume JC, Vaillant L, Bernard P, et al. Controlled trial of azathioprine and plasma exchange in addition to prednisolone in the treatment of bullous pemphigoid. *Arch Dermatol*. 1993;129:49–53.
137. Dreno B, Sassolas B, Lacour P, et al. Methylprednisolone versus prednisolone methylsulphobenzoate in pemphigoid: a comparative multicenter study. *Ann Dermatol Venereol*. 1993;120:518–21.
138. Fivenson DP, Breneman DL, Rosen GB, et al. Nicotinamide and tetracycline therapy of bullous pemphigoid. *Arch Dermatol*. 1994;130:753–8.
139. Liu BG, Li ZY, Di M. Effect of Jingui Shenqi pill combined prednisone on expression of glucocorticoid receptor and its clinical effect in treating bullous pemphigoid patients. *Zhongqiao Zhong Xi Ji Jie He Za Zhi*. 2006;26:881–4.
140. Beissert S, Werfel T, Frieling U, et al. A comparison of oral methylprednisolone plus azathioprine or mycophenolate mofetil for the treatment of bullous pemphigoid. *Arch Dermatol*. 2007;143:1536–42.
141. Daniel BS, Borradori L, Hall RP, Murrell DF. Evidence-based management of bullous pemphigoid. *Dermatol Clin*. 2011;29:613–20.
142. Bernard P, Bedane C, Prost C, et al. Bullous pemphigoid. Guidelines for the diagnosis and treatment. Centres de référence des maladies bulleuses auto-immunes. Société Française de Dermatologie [in French]. *Ann Dermatol Venereol*. 2011;138:247–51.
143. Venning VA, Thagipour K, Mohd Mustapa MF, et al. British Association of Dermatologists' guidelines for the management of bullous pemphigoid. *Br J Dermatol*. 2012;167:1200–14.
144. Feliciani C, Joly P, Jonkman MF, et al. Management of bullous pemphigoid: the European Dermatology Forum consensus in collaboration with the European Academy of Dermatology and Venereology. *Br J Dermatol*. 2015;172:867–77.
145. Lebrun-Vignes V, Roujeau JC, Bernard P, et al. Prednisone is more effective than prednisolone metasulphobenzoate in the treatment of bullous pemphigoid. *Arch Dermatol*. 1999;135:89–90.
146. Terra JB, Potte WJ, Jonkman MF. Whole body application of a potent topical corticosteroid for bullous pemphigoid. *J Eur Acad Dermatol Venereol*. 2014;28:712–8.
147. Sobocinski V, Duvert-Lehembre S, Bubenheim M, et al. Assessment of compliance with topical corticosteroids in bullous pemphigoid patients. *Br J Dermatol*. 2016;174:919–21.
148. Bézier M, Reguiai Z, Vitry F, et al. Usefulness of thiopurine S-methyltransferase genotypic analysis in patients with autoimmune bullous diseases: a preliminary study. *Eur J Dermatol*. 2008;18:512–7.
149. Paul MA, Jorizzo JL, Fleischer AB Jr, White WL. Low-dose methotrexate treatment in elderly patients with bullous pemphigoid. *J Am Acad Dermatol*. 1994;31:620–5.
150. Kjellman P, Eriksson H, Berg P. A retrospective analysis of patients with bullous pemphigoid treated with methotrexate. *Arch Dermatol*. 2008;144:612–6.
151. Gurcan HM, Ahmed AR. Analysis of current data on the use of methotrexate in the treatment of pemphigus and pemphigoid. *Br J Dermatol*. 2009;161:723–31.
152. Du-Thanh A, Merlet S, Maillard H, et al. Combined treatment with low-dose methotrexate and initial short-term superpotent topical steroids in bullous pemphigoid: an open, multicenter, retrospective study. *Br J Dermatol*. 2011;165:1337–43.
153. Chave TA, Mortimer NJ, ShaH DS, Hutchinson PE. Chlorambucil as steroid-sparing agent in bullous pemphigoid. *Br J Dermatol*. 2004;151:1107–8.
154. Gual A, Iranzo P, Mascaro JM. Treatment of bullous pemphigoid with low-dose cyclophosphamide: a case series of 20 patients. *J Eur Acad Dermatol*. 2014;28:814–8.
155. Chalmers JR, Wojnarowska F, Kirtschig G, et al. A randomized controlled trial to compare the safety and effectiveness of doxycycline (200 mg daily) with oral prednisolone (0.5 mg kg⁻¹ daily) for initial treatment of bullous pemphigoid: a protocol for the Bullous Pemphigoid Steroids and Tetracyclines (BLISTER) Trial. *Br J Dermatol*. 2015;173:227–34.
156. Venning VA, Millard PR, Wojnarowska F. Dapsone as first line therapy for bullous pemphigoid. *Br J Dermatol*. 1989;120:83–92.
157. Bouscarat F, Chosidow O, Picard-Dahan C, et al. Treatment of bullous pemphigoid with dapsone: retrospective study of thirty-six cases. *J Am Acad Dermatol*. 1996;34:683–4.
158. Chu J, Bradley M, Marinkovitch MP. Topical tacrolimus is a useful adjunctive therapy for bullous pemphigoid. *Arch Dermatol*. 2003;139:813–5.
159. Ko MJ, Chu CY. Topical tacrolimus therapy for localized bullous pemphigoid. *Br J Dermatol*. 2003;149:1079–81.
160. Harman KE, Black MM. High-dose intravenous immune globulin for the treatment of autoimmune blistering diseases: an evaluation of its use in 14 cases. *Br J Dermatol*. 1999;140:865–74.
161. Ahmed AR. Intravenous immunoglobulin therapy for patients with bullous pemphigoid unresponsive to conventional immunosuppressive treatment. *J Am Acad Dermatol*. 2001;45:825–35.
162. Gaitanis G, Alexis I, Pelidou SH, et al. High dose intravenous immunoglobulins in the treatment of adult patients with bullous pemphigoid. *Eur J Dermatol*. 2012;22:363–9.
163. Guillot B, Donadio D, Guilhou JJ, et al. Long term plasma exchange therapy in bullous pemphigoid. *Acta Derm Venereol*. 1986;66:73–5.
164. Müller PA, Bröcker EB, Klinker E, et al. Adjuvant treatment of recalcitrant bullous pemphigoid with immunoabsorption. *Dermatology*. 2012;224:224–7.

165. Schmidt E, Seitz CS, Benoit S, et al. Rituximab in autoimmune bullous diseases: mixed responses and adverse effects. *Br J Dermatol*. 2007;156:352–6.
166. Reguiai Z, Tchen T, Perceau G, et al. Efficacy of rituximab in a case of refractory bullous pemphigoid. *Ann Dermatol Venereol*. 2009;136:431–4.
167. Kasperkiewicz M, Shimanovitch I, Ludwig R, et al. Rituximab for treatment-refractory pemphigus and pemphigoid. *J Am Acad Dermatol*. 2011;65:552–8.
168. Hall RP 3rd, Streilein RD, Hannah DL, McNair PD, Fairley JA, Ronaghy A, et al. Association of serum B-cell activating factor level and proportion of memory and transitional B cells with clinical response after rituximab treatment of bullous pemphigoid patients. *J Invest Dermatol*. 2013;133:2786–8.
169. Yamauchi PS, Lowe NJ, Gindi V. Treatment of coexisting bullous pemphigoid and psoriasis with the tumour necrosis factor antagonist etanercept. *J Am Acad Dermatol*. 2006;54:S121–2.
170. Ahmed AR, Shetty S, Spigelman S. Treatment of recalcitrant bullous pemphigoid with a novel protocol: a retrospective study with a 6-year follow-up. *J Am Acad Dermatol*. 2016;74:700–8.
171. Fairley J, Baum CL, Brandt DS, et al. Pathogenicity of IgE autoimmunity: successful treatment of bullous pemphigoid with omalizumab. *J Allergy Clin Immunol*. 2009;123:704–5.
172. Yu KK, Crew AB, Messingham KA, Fairley JA, Woodley DT. Omalizumab therapy for bullous pemphigoid. *J Am Acad Dermatol*. 2014;71:468–74.
173. Boussemart L, Jacobelli Batteux F, et al. Auto-immune bullous skin diseases occurring under anti-tumor necrosis factor therapy. *Dermatology*. 2010;221:201–5.
174. Plée J, Le Jan S, Giustiniani J, et al. Integrating longitudinal serum IL-17 and IL-23 follow-up, along with autoantibodies, contributes to predict bullous pemphigoid outcome. *Sci Rep*. 2015;5:18001.
175. Loget J, Plee J, Antonicelli F, Bernard P. A successful treatment with ustekinumab in a case of relapsing bullous pemphigoid associated with psoriasis. *J Eur Acad Dermatol*. Epub 12 Oct 2016. doi:[10.1111/jdv.14002](https://doi.org/10.1111/jdv.14002).
176. Nakayama C, Fujita Y, Watanabe M, et al. Development of bullous pemphigoid during treatment of psoriatic onychopachydermo periostitis with ustekinumab. *J Dermatol*. 2015;42:996–8.
177. Cai SC, Lim YL, Li W, et al. Anti-BP180 NC16A titres as an indicator of disease activity and outcome in Asian with bullous pemphigoid. *Ann Acad Med Singap*. 2015;44:119–26.
178. Ingen-Housz-Oro S, Plee J, Belmondo T, et al. Positive direct immunofluorescence is of better value than ELISA-BP180 and ELISA-BP230 values for the prediction of relapse after treatment cessation in bullous pemphigoid: a retrospective study of 97 patients. *Dermatology*. 2015;231:50–5.